

Otterbein University

Digital Commons @ Otterbein

Nursing Student Class Projects (Formerly MSN)

Student Research & Creative Work

Summer 2016

Congenital Syphilis

Natalie T. Bennett

Otterbein University, natalie.bennett@otterbein.edu

Follow this and additional works at: https://digitalcommons.otterbein.edu/stu_msn



Part of the [Nursing Commons](#)

Recommended Citation

Bennett, Natalie T., "Congenital Syphilis" (2016). *Nursing Student Class Projects (Formerly MSN)*. 173.
https://digitalcommons.otterbein.edu/stu_msn/173

This Project is brought to you for free and open access by the Student Research & Creative Work at Digital Commons @ Otterbein. It has been accepted for inclusion in Nursing Student Class Projects (Formerly MSN) by an authorized administrator of Digital Commons @ Otterbein. For more information, please contact digitalcommons07@otterbein.edu.

Congenital Syphilis

Natalie Bennett BSN, RN

Otterbein University, Westerville, Ohio

Introduction

Despite available prevention and treatment measures, congenital syphilis is on the rise again in the United States (Su et al, 2016). Congenital syphilis is caused by maternal infection during pregnancy with the bacteria *Treponema pallidum*, which is then transmitted to the fetus. Complications include miscarriage, fetal and neonatal death, premature birth, and other anomalies in the newborn. The leading factor in congenital syphilis infection is limited or no prenatal care (Dobson, 2016). If the syphilis-infected mother is treated during pregnancy, infection of the fetus can be prevented (Su et al, 2016). Nurses and health care providers need to be well informed on the risk factors and be able to rapidly diagnose congenital syphilis so that treatment can be initiated, leading to decreased fetal and neonatal mortality.

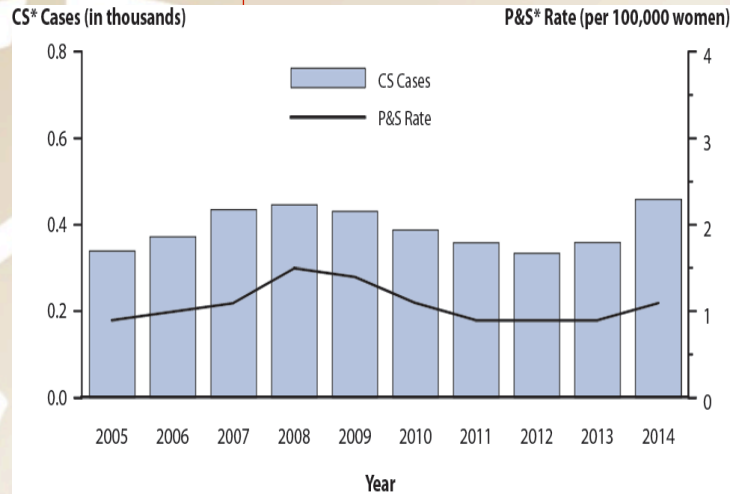
Underlying Pathophysiology and Significance

Syphilis infection spreads from an infected person to the next when the spirochete *Treponema pallidum* crosses through skin or mucous membranes during sexual contact including oral, vaginal and/or anal sex. *T. pallidum* is a small, fragile, spiraled body that can move quickly to invade the new host. It exits the primary host through an infectious lesion, and from there is capable of penetrating intact membranes or may enter the body through microscopic breaks in the skin (Kwak & Lamprecht, 2015). Infection can also spread through blood transfusions, which is rare now due to screening processes, but still possible in early infection in which blood testing may still come back negative.

If an infected woman is or becomes pregnant, *T. Pallidum* can cross the placenta and infect the fetus at any point during the pregnancy. Additionally, a neonate can be infected through exposure to a lesion during the birth process (Berman, 2004). Syphilis infection in pregnancy has a high rate of spontaneous abortion and stillbirth.

Within a few hours of entering the host, the organism has spread through the lymphatic system and entered systemic circulation, causing widespread infection. The primary stage in which infection lesions appear can take several weeks to manifest in acquired maternal syphilis. In congenital syphilis, however, there is not a primary stage and manifestations of disease begin in the second stage. The central nervous system is typically the first area that is invaded in secondary syphilis (Dobson, 2016). In latent syphilis, the patient may be asymptomatic but will still have positive lab testing. Tertiary syphilis is rare now due to available treatment and causes neurological issues including dementia, as well as cardiovascular complications. It should be noted that syphilis infection will not progress to the next stage if treatment is initiated and successful (Mulryan, 2013).

Figure 1



Trends in Congenital Syphilis, 2005-2014

CS= Congenital Syphilis P&S Primary and Secondary Syphilis
Retrieved July 10, 2016 from <http://www.cdc.gov/std/stats14/figures/46.htm>

Clinical Manifestations

Maternal

Primary infection:
• Skin chancre on the genital, oral or anal region.
• Lymphadenopathy

Secondary:

- fatigue,
- fever,
- headache,
- Lymphadenopathy,
- skin rashes and patches,
- Warts,
- hair loss

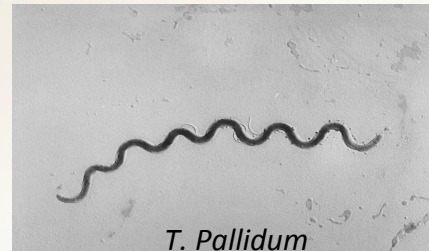
Latent Stage: Often asymptomatic
Tertiary Stage:

- Cardiac: Aortitis, aneurysm, Heart valve failure
- Neurological: Palsies, paralysis Ataxia, dementia, sensory disturbances,
- Seizures, strokes
- Gummatous: Distinct skin and bone lesions

Neonatal

- Hepatomegaly
- Lymphadenopathy
- Hematological disturbances (anemia)
- Hydrops fetalis
- Skin lesions
- Rhinitis and nasal stuffiness
- Renal abnormalities
- Bone involvement (osteochondritis or periostitis, can cause pain)
- Glaucoma and cataracts
- Neurological impairment
- Sepsis leading to death

Figure 2



Retrieved July 10, 2016 from <http://home.apu.edu/~jsimons/Bio101/graphics/spirillum.gif>

Diagnosis and Treatment

Maternal syphilis can be diagnosed through serum testing. Two major types of testing exist: nontreponemal and treponemal. Nontreponemal tests (RPR and VDRL) are used for screening only; the treponemal test is confirmatory. If a patient has both positive nontreponemal and treponemal tests, she is presumed to be positive for syphilis. The treatment of choice for maternal syphilis is penicillin. Current guidelines recommend 2.4 million international units to be administered parentally once a week for at least two weeks. Serum titers can be drawn to ensure efficacy. Patients with an allergy need to be desensitized and still treated with penicillin.

Treatment should be initiated as soon as possible to minimize transmission to the fetus. Sexual partners of the patient need to be treated as well to prevent reinfection (Lago, 2016). Congenital syphilis is also diagnosed through nontreponemal and treponemal blood testing. Results of the mother's testing are used for diagnosis as well. Other recommended tests include cerebrospinal fluid evaluation, complete blood count, x-rays of affected bones, brain ultrasound, and liver function tests. The eyes and hearing should be evaluated for involvement. The treatment of choice is a 10-day course of parenteral penicillin (Dobson 2015).

Nursing Implications

Nurses and health care providers who work in women's health need to be vigilant in screening for syphilis. All women should be screened during pregnancy (Follett & Clarke, 2011). In high-risk populations, testing may need to be repeated more than once during the pregnancy. When caring for a neonate, the health care provider should review maternal history and testing; if unavailable, the neonate should be tested as well. Currently, no vaccine exists to prevent syphilis. Prevention can be achieved through patient education on safe sex and the importance of early and comprehensive prenatal care.

Syphilis is a reportable disease in the United States and health care providers should contact the local health department upon each patient diagnosis. When congenital syphilis is diagnosed, siblings of the child should be considered for screening if not previously performed (Dobson, 2015). Patients positive for syphilis should also be screened for HIV because of the increased risk for infection of other sexually transmitted diseases. Because HIV depletes the immune system, syphilis infection is common in those infected with HIV (Mulryan, 2013).

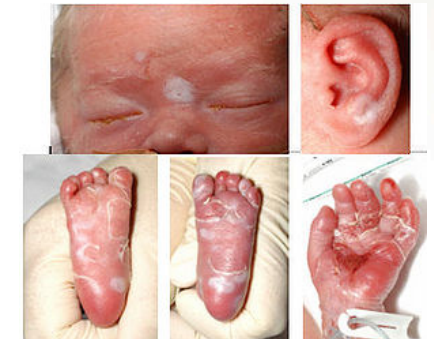Conclusion

Congenital syphilis occurs when *T. Pallidum* spreads from an infected mother to her unborn child. It has devastating consequences, including fetal and neonatal death. Congenital continues to pose a public health threat; but it should not. With adequate prenatal care, screenings, education and treatment are available to prevent congenital syphilis. The recent increase of congenital syphilis infections demonstrates the need for increased vigilance in screening all pregnant women.

References

- Berman, S. M. (2004, June). Maternal syphilis: Pathophysiology and treatment. *Bulletin of the World Health Organization*, 84(6), 433-438.
- Santis, M. D., Luca, C. D., Mappa, I., Spagnuolo, T., Licameli, A., Straface, G., & Scambia, G. (2012). Syphilis infection during pregnancy: Fetal risks and clinical management. *Infectious Diseases in Obstetrics and Gynecology*, 20(12), 1-5. doi: 10.1155/2012/430585
- Dobson, S.R. (2016). Congenital syphilis: Clinical features and diagnosis. In UpToDate, Armsby, C. (Ed), UpToDate, Waltham, MA.
- Dobson, S.R. (2015). Congenital syphilis: Evaluation, management, and prevention. In UpToDate, Armsby, C. (Ed), UpToDate, Waltham, MA.
- Follett, T., & Clarke, D. F. (2011). Resurgence of congenital syphilis: Diagnosis and treatment. *Neonatal Network*, 30(5), 320-328. doi:10.1891/07300832.30.5.320
- Kwak, J., & Lamprecht, C. (2015). A review of the guidelines for the evaluation and treatment of congenital syphilis. *Pediatric Annals*, 44(5), E108-114. doi: 10.3928/00904481-20150512-10
- Lago, E. G. (2016). Current perspectives on prevention of mother-to-child transmission of syphilis. *Cureus*, 8(3), e525, 1-20. doi:10.7759/cureus.525
- Mulryan, C. (2013). Syphilis: Recognizing the 'great pretender'. *Practice Nursing*, 24(5), 217-221.
- Stamm, L. V. (2015). Syphilis: Antibiotic treatment and resistance. *Epidemiology and Infection*, 143(08), 1567-1574. doi:10.1017/s0950268814002830
- Su, J. R., Brooks, L. C., Davis, D. W., Torrone, E. A., Weinstock, H. S., & Kamb, M. L. (2016). Congenital syphilis: Trends in mortality and morbidity in the United States, 1999 through 2013. *American Journal of Obstetrics and Gynecology*, 214(3), 381.e1-381.e9. doi:10.1016/j.ajog.2015.10.007

Figure 3: Skin Abnormalities in a Syphilis-Infected Neonate



Retrieved July 10, 2016 from https://microbewiki.kenyon.edu/index.php/Syphilis_in_Sub-Saharan_Africa



OTTERBEIN
UNIVERSITY